

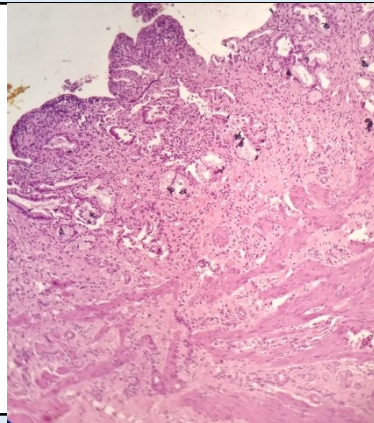
Patient Name	Mrs. RINKI	Client Name	Civil Hospital-P	Specimen Received	19/01/2019
Age/Sex	22 Years/Female	Client Code	MolQ1681P	Specimen Type	Tissue
Patient ID	011901190103	Ref. Doctor	DR SAURABH DESHWAL	Collection Date	19/01/2019
Specimen ID	MOLQ/B-104/19			Report Date	23/01/2019

SURGICAL PATHOLOGY REPORT

GALL BLADDER.

DIAGNOSIS

CHOLECYSTITIS WITH CHOLELITHIASIS



SPECIMEN

Gall Bladder.

GROSS

Received 6.5x2.2cm long gall bladder. Cut section shows stone.

Microscopy

- Section examined shows ulcerative mucosa and Rokitansky-Aschoff sinuses (irregularly shaped tubular structures lined by cuboidal lining epithelium with round to oval nucleus) with fibro collagenous tissue and inflammatory cells (lymphocytes).

Note : All biopsy specimen will be stored for 15 (fifteen) days, block and slides for 5 (five) years only from the time of receipt at the laboratory. No request, for any of the above, will be entertained after the due date.

Reference

- Rosai and Ackerman's Surgical Pathology.
- Modern Surgical Pathology.

Gulshan Yadav, MD
Consultant Pathologist