

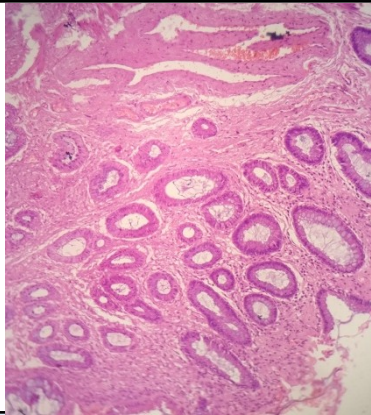
Patient Name	Mr. AB SALAM /ANG	Client Name	Patients Care Clinical	Specimen Received	18/01/2019
Age/Sex	45 Years/Male		Laboratory, Jammu Kashmir	Specimen Type	Tissue
Patient ID	011901170316	Client Code	MolQ1839P	Collection Date	18/01/2019
Specimen ID	MOLQ/B-100/19	Ref. Doctor	NEW GEO CLI LAB	Report Date	21/01/2019

SURGICAL PATHOLOGY REPORT

Hemorrhoids

DIAGNOSIS

HEMORRHOIDS



SPECIMEN
Hemorrhoids

GROSS

Received 6.4 x 2.9 cm long gall bladder already cut open.

Microscopy

- Section examined shows squamous lining epithelium, submucosal glands, fibro collagenous tissue with blood vessels.No granuloma and no malignant cells seen.

Note : All biopsy specimen will be stored for 15 (fifteen)days, block and slides for 5(five) years only from the time of receipt at the laboratory. No request ,for any of the above ,will be entertained after the due date.

Reference

- Rosai and Ackerman's Surgical Pathology.
- Modern Surgical Pathology.

Gulshan Yadav, MD
Consultant Pathologist