

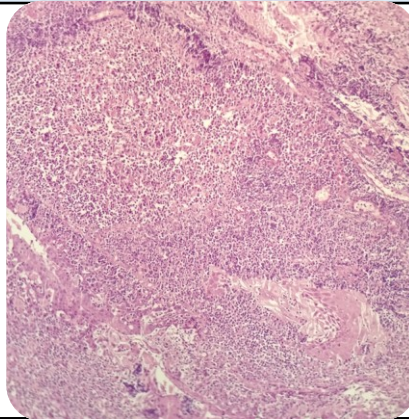
Patient Name	Mr. SHASHI	Client Name	SKD Memorials Sahara Hospital	Specimen Received	16/01/2019
Age/Sex	37 Years/Male			Specimen Type	Tissue
Patient ID	011901160084	Client Code	MolQ1831P	Collection Date	16/01/2019
Specimen ID	MOLQ/B-83/19	Ref. Doctor		Report Date	18/01/2019

SURGICAL PATHOLOGY REPORT

Both tonsil

DIAGNOSIS

BILATERAL TONSILITIS



SPECIMEN

Both tonsil

GROSS

Received 1x1cm and 2x1.5 cm two greyish white tissue piece.

Microscopy

1. Section examined shows squamous lining epithelial having round nucleus with large number of lymphoid follicles, muscle bundles and few minor salivary glands.
2. No malignant cells and no granuloma seen.

Note : All biopsy specimen will be stored for 15 (fifteen) days, block and slides for 5 (five) years only from the time of receipt at the laboratory. No request, for any of the above, will be entertained after the due date.

Reference

- i) Rosai and Ackerman's Surgical Pathology.
- ii) Modern Surgical Pathology.

Gulshan Yadav, MD
Consultant Pathologist