

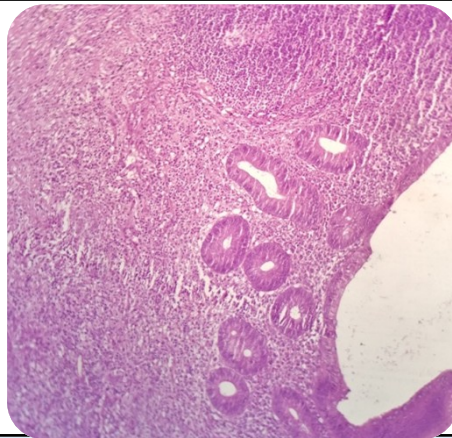
<b>Patient Name</b>	<b>Mr. NAVEEN</b>	<b>Client Name</b>	Kamal Hospital and Maternity Centre	<b>Specimen Received</b>	16/01/2019
<b>Age/Sex</b>	16 Years/Male	<b>Client Code</b>	MolQ1329CM	<b>Specimen Type</b>	Tissue
<b>Patient ID</b>	011901160064	<b>Ref. Doctor</b>		<b>Collection Date</b>	16/01/2019
<b>Specimen ID</b>	MOLQ/B-81/19			<b>Report Date</b>	18/01/2019

## SURGICAL PATHOLOGY REPORT

### APPENDIX.

#### DIAGNOSIS

**ACUTE APPENDICITIS.**



#### **SPECIMEN**

Appendix.

#### **GROSS**

Received 5x1.8cm long appendix. Cut section shows feco-lith

#### **Microscopy**

1. Section examined shows lymphoid follicles with ulcerative mucosa.
2. Deeper tissue shows inflammatory cells.

**Note :** All biopsy specimen will be stored for 15 (fifteen) days, block and slides for 5 (five) years only from the time of receipt at the laboratory. No request, for any of the above, will be entertained after the due date.

#### **Reference**

- i) Rosai and Ackerman's Surgical Pathology.
- ii) Modern Surgical Pathology.

**Gulshan Yadav, MD  
Consultant Pathologist**