

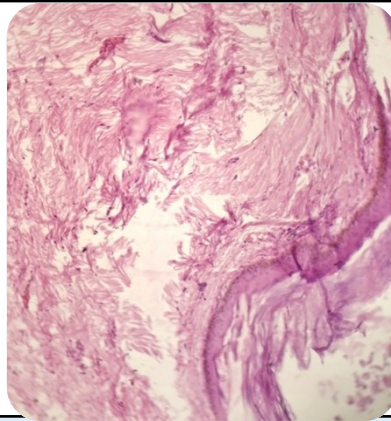
<b>Patient Name</b>	Miss. POOJA	<b>Client Name</b>	Civil Hospital-P, Gurgaon	<b>Specimen Received</b>	14/01/2019
<b>Age/Sex</b>	16 Years/Female	<b>Client Code</b>	MolQ1681P	<b>Specimen Type</b>	Tissue
<b>Patient ID</b>	011901140135	<b>Ref. Doctor</b>	SAURABH CHANDRA	<b>Collection Date</b>	14/01/2019
<b>Specimen ID</b>	MOLQ/B-74/19			<b>Report Date</b>	16/01/2019

## SURGICAL PATHOLOGY REPORT

### Sebaceous cyst

#### DIAGNOSIS

**SEBACEOUS CYST**



#### SPECIMEN

Sebaceous cyst wall

#### GROSS

Received 4x3cm greyish white tissue piece cut section shows necrotic material.

#### Microscopy

1. Section examined shows Squamous lining epithelial, keratin flakes with underlining connective tissue.

**Note :** All biopsy specimen will be stored for 15 (fifteen)days, block and slides for 5(five) years only from the time of receipt at the laboratory. No request ,for any of the above ,will be entertained after the due date.

#### Reference

- i) Rosai and Ackerman's Surgical Pathology.
- ii) Modern Surgical Pathology.

**Gulshan Yadav, MD**  
Consultant Pathologist