

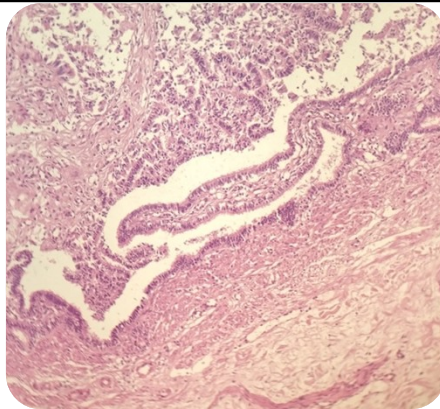
<b>Patient Name</b>	<b>Mrs. APANA</b>	<b>Client Name</b>	Civil Hospital-P	<b>Specimen Received</b>	11/01/2019
<b>Age/Sex</b>	32 Years/Female	<b>Client Code</b>	MolQ1681P	<b>Specimen Type</b>	Tissue
<b>Patient ID</b>	011901110027	<b>Ref. Doc</b>	DR.KIRANMEET SARAN	<b>Collection Date</b>	11/01/2019
<b>Specimen ID</b>	MOLQ/B-62/19			<b>Report Date</b>	16/01/2019

**SURGICAL PATHOLOGY REPORT**

**Fallopian tube**

**DIAGNOSIS**

**Fallopian tube confirmed and unremarkable.**



**SPECIMEN**

Fallopian tube

**GROSS**

Received autolyzid single greyish white tissue piece.

**Microscopy**

- Section examined shows tubal lining epithelial with surrounding tissue.  
No granuloma seen.

**Note :** All biopsy specimen will be stored for 15 (fifteen) days, block and slides for 5 (five) years only from the time of receipt at the laboratory. No request ,for any of the above will be entertained after the due date.

**Reference**

- Rosai and Ackerman's Surgical Pathology.
- Modern Surgical Pathology.

**Gulshan Yadav, MD  
Consultant Pathologist**