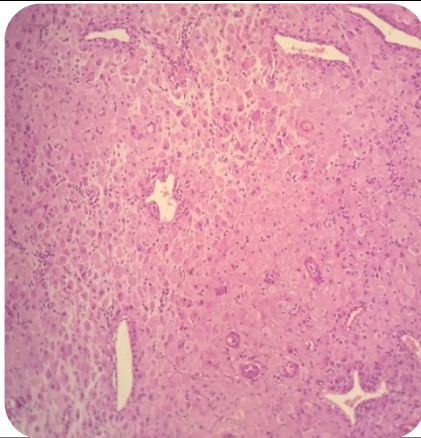


Patient Name	Mrs. POOJA	Client Name	North Delhi Diagnostic,	Specimen Received	10-Jan-2019
Age/Sex	25/F		New Delhi	Specimen Type	Tissue
Patient ID	011901100063	Client Code	MolQ1394CM	Collection Date	10-Jan-2019
Specimen ID	MOLQ/B-52/19	Ref. Doctor	Dr. SUSHMA PASSI	Report Date	15-Jan-2019

SURGICAL PATHOLOGY REPORT

ENDOMETRIUM

DECIDUAL CAST



SPECIMEN

Endometrium

GROSS

Received multiple greyish white tissue piece.

Microscopy

1. Section examined shows endometrial glands with decidual cells and mononuclear inflammatory cells.
2. No malignant cells and no granuloma seen.

Note : All biopsy specimen will be stored for 15 (fifteen) days, block and slides for 5 (five) years only from the time of receipt at the laboratory. No request for any of the above, will be entertained after the due date.

Reference

- i) Rosai and Ackerman's Surgical Pathology.
- ii) Modern Surgical Pathology.

Gulshan Yadav, MD
Consultant Pathologist