

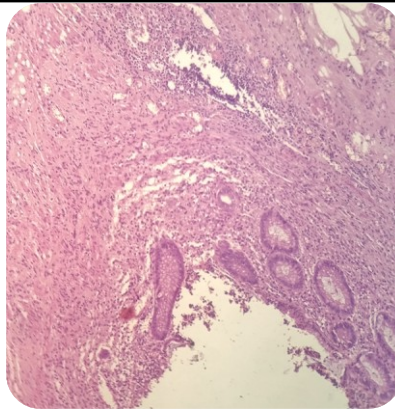
|                     |                    |                    |                             |                          |            |
|---------------------|--------------------|--------------------|-----------------------------|--------------------------|------------|
| <b>Patient Name</b> | Mr. ISHTIYAQ AHMAD | <b>Client Name</b> | Danish Lab, Jammu & Kashmir | <b>Specimen Received</b> | 13/01/2019 |
|                     | SOPORE             | <b>Client Code</b> |                             | <b>Specimen Type</b>     | Tissue     |
| <b>Age/Sex</b>      | 36 YRS/M           | <b>Ref. Doc</b>    |                             | <b>Collection Date</b>   | 13/01/2019 |
| <b>Patient ID</b>   | 011901130222       |                    |                             | <b>Report Date</b>       | 15/01/2019 |
| <b>Specimen ID</b>  | MOLQ/B-73/19       |                    |                             |                          |            |

## SURGICAL PATHOLOGY REPORT

### Appendix

#### DIAGNOSIS

**ACUTE APPENDICITIS.**



#### SPECIMEN

Appendix

#### GROSS

Received 6.5x1.1cm long appendix. Cut section shows fecolith

#### Microscopy

Section examined shows lymphoid follicles with ulcerative mucosa. Deeper tissue shows inflammatory cells.

**Note :** All biopsy specimen will be stored for 15 (fifteen) days, block and slides for 5 (five) years only from the time of receipt at the laboratory. No request ,for any of the above will be entertained after the due date.

#### Reference

- i) Rosai and Ackerman's Surgical Pathology.
- ii) Modern Surgical Pathology.

**Gulshan Yadav, MD**  
Consultant Pathologist