

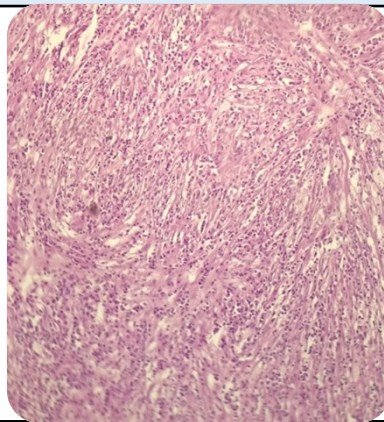
| | | | | | |
|---------------------|--------------|--------------------|---------------------------|--------------------------|------------|
| Patient Name | Mrs. GEETA | Client Name | Life Care Path Lab, Tauru | Specimen Received | 12/01/2019 |
| Age/Sex | 30 YRS/F | Client Code | MolQ1518P | Specimen Type | Tissue |
| Patient ID | 011901120248 | Ref. Doc | | Collection Date | 12/01/2019 |
| Specimen ID | MOLQ/B-67/19 | | | Report Date | 15/01/2019 |

SURGICAL PATHOLOGY REPORT

Right ovarian cyst.

DIAGNOSIS

DERMOID CYST



SPECIMEN

Right ovarian cyst.

GROSS

Received 11x7.5cm greyish white tissue piece. Cut section shows cheesy and necrotic material with hair material and tube.

Microscopy

1. Section examined shows fibrocollagenous tissue, glands, blood vessels with hair. Tube unremarkable.
2. No malignant cells and no granuloma seen.

Note : All biopsy specimen will be stored for 15 (fifteen) days, block and slides for 5 (five) years only from the time of receipt at the laboratory. No request ,for any of the above will be entertained after the due date.

Reference

- i) Rosai and Ackerman's Surgical Pathology.
- ii) Modern Surgical Pathology.

Gulshan Yadav, MD
Consultant Pathologist