

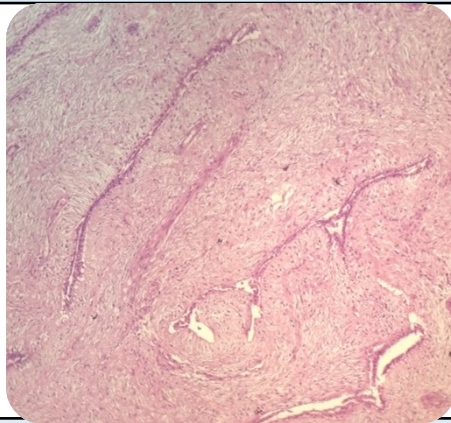
Patient Name	Miss. SADIYA JAN 7184	Client Name	Patients Care Clinical Laboratory,	Specimen Received	10/01/2019
Age/Sex	17 Years/Female		Jammu & Kashmir	Specimen Type	Tissue
Patient ID	011901100216	Client Code	MolQ1839P	Collection Date	10/01/2019
Specimen ID	MOLQ/B-57/19	Ref. Doctor	LIFE CARE DOORU	Report Date	14/01/2019

SURGICAL PATHOLOGY REPORT

Left breast Fibroadenoma

DIAGNOSIS

FIBROADENOMA



SPECIMEN

Left breast Fibroadenoma

GROSS

Received 2x3 cm greyish white tissue piece.

Microscopy

Section examined shows cystically dilated ducts with cuboidal epithelium with small round nucleus surrounded by fibrocollagenous tissue.

No granuloma seen.

No malignant cells seen.

Note : All biopsy specimen will be stored for 15 (fifteen)days, block and slides for 5(five) years only from the time of receipt at the laboratory. No request ,for any of the above ,will be entertained after the due date.

Reference

- i) Rosai and Ackerman's Surgical Pathology.
- ii) Modern Surgical Pathology.

**Gulshan Yadav, MD
Consultant Pathologist**