

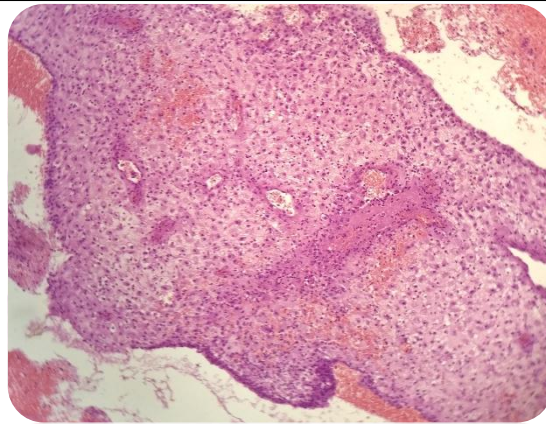
Patient Name	Mrs. MAMTA	Client Name	Brijanand Path Lab	Specimen Received	10/01/2019
Age/Sex	45/F	Client Code	MOLQ1133CM	Specimen Type	Tissue
Patient ID	011901100132	Ref. Doctor		Collection Date	10/01/2019
Specimen ID	MOLQ/B-53/19			Report Date	12/01/2019

SURGICAL PATHOLOGY REPORT

Endometrium

DIAGNOSIS

HYPERPROGESTRONIC EFFECT



SPECIMEN

Endometrium

GROSS

Received 1x1cm greyish white tissue piece.

Microscopy

1. Section examined shows small endometrial glands with columnar lining with small round nucleus and endocervical cells. Stroma shows mono nuclear inflammatory cells.
2. No malignant cells and no granuloma seen.

Note : All biopsy specimen will be stored for 15 (fifteen) days, block and slides for 5 (five) years only from the time of receipt at the laboratory. No request, for any of the above, will be entertained after the due date.

Reference

- i) Rosai and Ackerman's Surgical Pathology.
- ii) Modern Surgical Pathology.

Gulshan
Gulshan Yadav, MD
Consultant Pathologist