

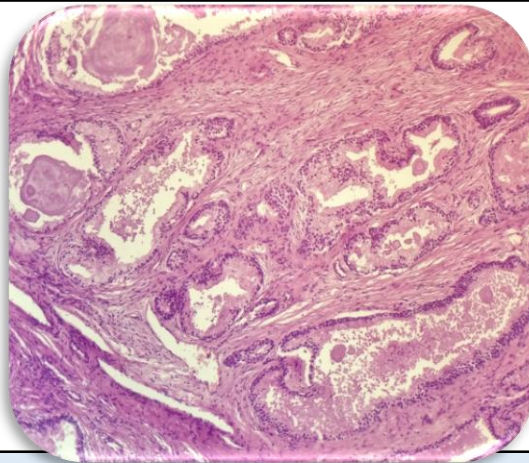
<b>Patient Name</b>	Mr. LIYAKAT	<b>Client Name</b>	Murad Hospital, Nuh	<b>Specimen Received</b>	09/01/2019
<b>Age/Sex</b>	27 YRS/M	<b>Client Code</b>	MolQ1830P	<b>Specimen Type</b>	Tissue
<b>Patient ID</b>	011901090175	<b>Ref. Doctor</b>		<b>Collection Date</b>	09/01/2019
<b>Specimen ID</b>	MOLQ/B-49/19			<b>Report Date</b>	11/01/2019

## SURGICAL PATHOLOGY REPORT

Prostrate

### DIAGNOSIS

**BENIGN PROSTATIC HYPERPLASIA.**



#### SPECIMEN

Prostrate

#### GROSS

Received 5x2cm greyish white tissue piece

#### Microscopy

- Section examined shows bilayered prostatic glands with columnar lining epithelium and with small round to oval nucleus surrounded by large number of fibrocollagenous tissue and mononuclear inflammatory cell.

**Note :** All biopsy specimen will be stored for 15 (fifteen)days, block and slides for 5(five) years only from the time of receipt at the laboratory. No request ,for any of the above ,will be entertained after the due date.

#### Reference

- Rosai and Ackerman's Surgical Pathology.
- Modern Surgical Pathology.

**Gulshan Yadav, MD**  
Consultant Pathologist