

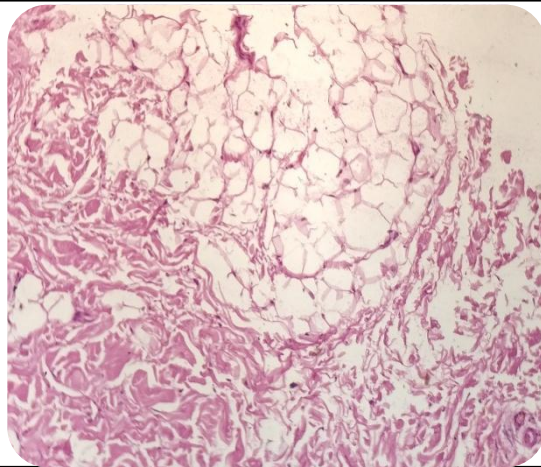
|                     |                          |                    |                                   |                          |            |
|---------------------|--------------------------|--------------------|-----------------------------------|--------------------------|------------|
| <b>Patient Name</b> | <b>Mr. ZAHOR AH 7269</b> | <b>Client Name</b> | Patients Care Clinical Laboratory | <b>Specimen Received</b> | 08/01/2019 |
| <b>Age/Sex</b>      | 35/M                     |                    | Jammu & Kashmir                   | <b>Specimen Type</b>     | Tissue     |
| <b>Patient ID</b>   | 011901080069             | <b>Client Code</b> | MolQ1833P                         | <b>Collection Date</b>   | 08/01/2019 |
| <b>Specimen ID</b>  | MOLQ/B-42/19             | <b>Ref. Doctor</b> |                                   | <b>Report Date</b>       | 11/01/2019 |

## SURGICAL PATHOLOGY REPORT

Lipoma

### DIAGNOSIS

**LIPOMA**



#### SPECIMEN

Lipoma

#### GROSS

Received 3x2cm greyish white tissue piece.

#### Microscopy

1. Section examined shows mature adipose cells and few inflammatory cells.
2. No malignant and no granuloma seen.

**Note :** All biopsy specimen will be stored for 15 (fifteen) days, block and slides for 5 (five) years only from the time of receipt at the laboratory. No request, for any of the above, will be entertained after the due date.

#### Reference

- i) Rosai and Ackerman's Surgical Pathology.
- ii) Modern Surgical Pathology.

**Gulshan Yadav, MD**  
Consultant Pathologist