

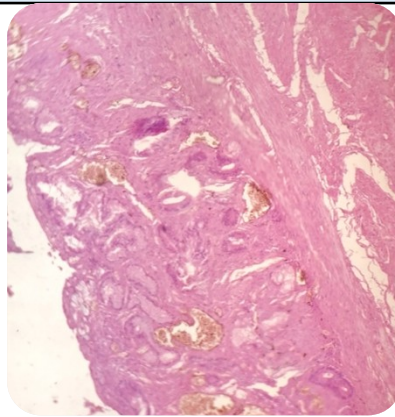
| | | | | | |
|---------------------|---|--------------------|------------------------------|--------------------------|------------|
| Patient Name | Mrs. ZAREEFA (W/O:- M.ASHRAF) NOWGAM | Client Name | New Unique Diagnostic Centre | Specimen Received | 08/01/2019 |
| Age/Sex | 40 Years/Female | Client Code | MolQ1833P | Specimen Type | Tissue |
| Patient ID | 011901080116 | Ref. Doc | BILAL LAB SUMBAL | Collection Date | 08/01/2019 |
| Specimen ID | MOLQ/B-41/19 | | | Report Date | 10/01/2019 |

SURGICAL PATHOLOGY REPORT

GALL BLADDER.

DIAGNOSIS

CHOLECYSTITIS AND CHOLELITHIASIS.



SPECIMEN

Gall Bladder.

GROSS

Received 6.2x2.8cm long gall bladder.

Microscopy

- Section examined shows ulcerative mucosa and Rokitansky-Aschoff sinuses with fibrocollagenous tissue and inflammatory cells.

Note : All biopsy specimen will be stored for 15 (fifteen) days, block and slides for 5 (five) years only from the time of receipt at the laboratory. No request, for any of the above will be entertained after the due date.

Reference

- Rosai and Ackerman's Surgical Pathology.
- Modern Surgical Pathology.

**Gulshan Yadav, MD
Consultant Pathologist**