

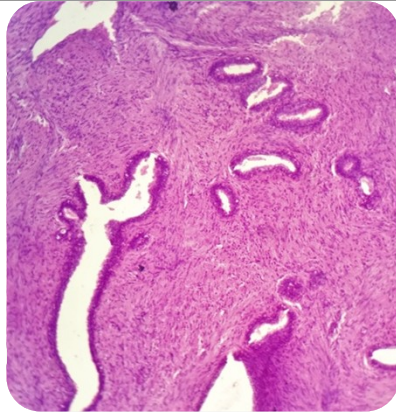
<b>Patient Name</b>	Mrs. SANGEETA	<b>Client Name</b>	Civil Hospital-P	<b>Specimen Received</b>	08/01/2019
<b>Age/Sex</b>	18/F		Gurgaon	<b>Specimen Type</b>	Tissue
<b>Patient ID</b>	011901080023	<b>Client Code</b>	MolQ1681P	<b>Collection Date</b>	08/01/2019
<b>Specimen ID</b>	MOLQ/B-40/19	<b>Ref. Doctor</b>		<b>Report Date</b>	10/01/2019

## SURGICAL PATHOLOGY REPORT

### Right breast Fibroadenoma

#### DIAGNOSIS

#### FIBROADENOMA



#### SPECIMEN

Right breast Fibroadenoma

#### GROSS

Received 1x1cm greyish white tissue piece.

#### Microscopy

1. Section examined shows cystically dilated ducts with cuboidal epithelium with small round nucleus surrounded by fibro collagenous tissue.
2. No granuloma seen.
3. No malignant cells seen.

**Note :** All biopsy specimen will be stored for 15 (fifteen)days, block and slides for 5(five) years only from the time of receipt at the laboratory. No request ,for any of the above ,will be entertained after the due date.

#### Reference

- i) Rosai and Ackerman's Surgical Pathology.
- ii) Modern Surgical Pathology.

**Gulshan Yadav, MD**  
Consultant Pathologist