

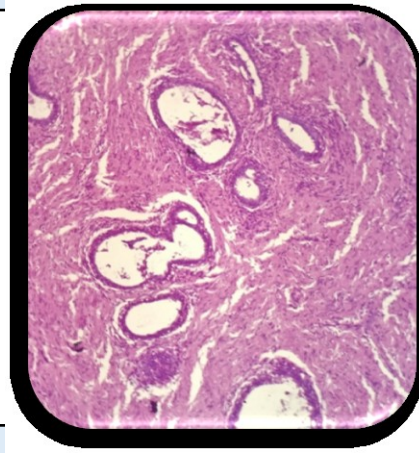
<b>Patient Name</b>	Miss. POOJA YADAV	<b>Client Name</b>	Lifeaid Wellness Centre	<b>Specimen Received</b>	07/01/2019
<b>Age/Sex</b>	14/F		Gurgaon	<b>Specimen Type</b>	Tissue
<b>Patient ID</b>	011901070235	<b>Client Code</b>	MolQ1476CM	<b>Collection Date</b>	07/01/2019
<b>Specimen ID</b>	MOLQ/B-34/19	<b>Ref. Doctor</b>		<b>Report Date</b>	10/01/2019

## SURGICAL PATHOLOGY REPORT

### Fibroadenoma of Right Breast

#### DIAGNOSIS

**BENIGN BREAST LESION**



#### SPECIMEN

Fibroadenoma of Right Breast

#### GROSS

Received 4x2.9 cm greyish white tissue piece, well encapsulated.

#### Microscopy

1. Section examined ducts lined by cuboidal lining epithelium, few ducts are dilated surrounded by fibro collagenous tissue.
2. No malignant cells and no granuloma seen.

**Note :** All biopsy specimen will be stored for 15 (fifteen)days, block and slides for 5(five) years only from the time of receipt at the laboratory. No request ,for any of the above ,will be entertained after the due date.

#### Reference

- i) Rosai and Ackerman's Surgical Pathology.
- ii) Modern Surgical Pathology.

**Gulshan Yadav, MD  
Consultant Pathologist**