

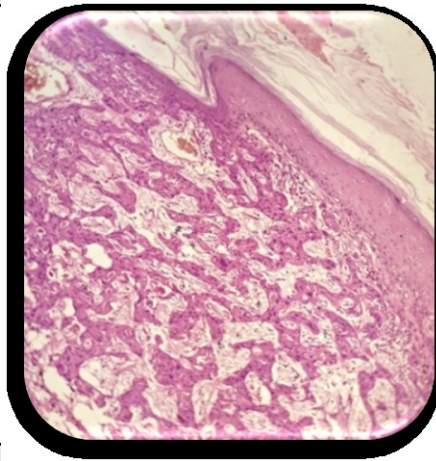
Patient Name	Mr. RAJKUMAR	Client Name	Lifeaid Wellness Centre	Specimen Received	29/12/2018
Age/Sex	60/M		Gurgaon	Specimen Type	Tissue
Patient ID	011812290210	Client Code	MolQ1476CM	Collection Date	29/12/2018
Specimen ID	MOLQ/B-1516-18	Ref. Doctor		Report Date	10/01/2019

SURGICAL PATHOLOGY REPORT

Recurrent Squamous Cell Carcinoma (Left Thigh Lesion)

DIAGNOSIS

MODERATELY DIFFERENTIATED SQUAMOUS CELL CARCINOMA



SPECIMEN

Recurrent Squamous Cell Carcinoma (Left Thigh Lesion)

Microscopy

. Main Mass: Section examined shows squamous lining epithelium with dysplastic features like altered N:C ratio, Pleomorphism, nuclear hyperchromatism, very few keratin pearl formation, dyskeratosis and few mitotic figures overlying the connective tissue stroma. There is break in the continuity of basement membrane and tumor epithelial cells invading the stroma in form of islands and cords. Stroma shows inflammatory cells and presence of necrosis.

Depth of Invasion upto dermis, adipose tissue not invaded.

2. Revised Anterior Margins: Negative for malignant cells.
3. Upper margins: Negative for malignant cells.
4. Lower margins: Negative for malignant cells.
5. Lateral margins: Negative for malignant cells.
6. Base: Negative for malignant cells.

Note : All biopsy specimen will be stored for 15 (fifteen) days, block and slides for 5 (five) years only from the time of receipt at the laboratory. No request for any of the above will be entertained after the due date.

Reference

- i) Rosai and Ackerman's Surgical Pathology.
- ii) Modern Surgical Pathology

GROSSING

Container 1: Received 5x4 cm greyish white tissue piece with skin, 3x3 cm lump. On grossing, the depth of tumor observed is 14.0 mm

Container 2: Received 2x0.5 cm greyish white tissue piece.

Gulshan Yadav, MD
Consultant Pathologist