

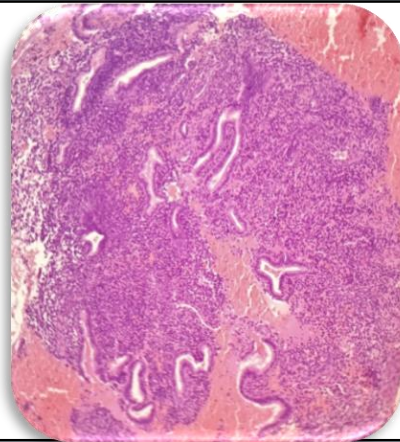
<b>Patient Name</b>	<b>Mrs. SHASHI</b>	<b>Client Name</b>	Civil Hospital-P	<b>Specimen Received</b>	05/01/2019
<b>Age/Sex</b>	39/F		Gurgaon	<b>Specimen Type</b>	Tissue
<b>Patient ID</b>	011901050122	<b>Client Code</b>	MolQ1681P	<b>Collection Date</b>	05/01/2019
<b>Specimen ID</b>	MOLQ/B-28/19 (Container 1)	<b>Ref. Doctor</b>		<b>Report Date</b>	08/01/2019

## SURGICAL PATHOLOGY REPORT

Fractional Curettage  
Container 1: Endometrial Curetting

### DIAGNOSIS

**PROLIFERATIVE PHASE**



#### SPECIMEN

Fractional Curettage  
Container 1: Endometrial Curetting

#### GROSSING

Received multiple greyish white tissue piece.

#### Microscopy

1. Section examined shows small endometrial glands having cuboidal epithelium with round to oval nucleus.
2. Stroma shows mononuclear inflammatory cells.
3. No malignant and no granuloma seen.

**Note :** All biopsy specimen will be stored for 15 (fifteen) days, block and slides for 5 (five) years only from the time of receipt at the laboratory. No request for any of the above will be entertained after the due date.

#### Reference

- i) Rosai and Ackerman's Surgical Pathology.
- ii) Modern Surgical Pathology

**Gulshan Yadav, MD**  
Consultant Pathologist