

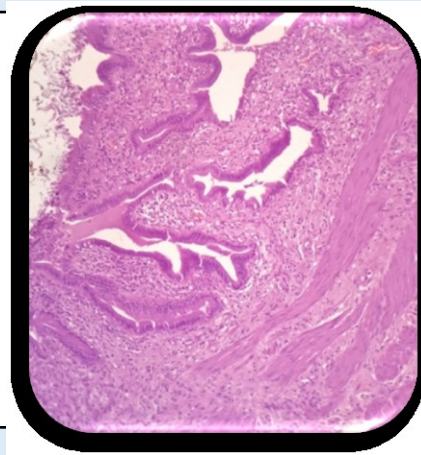
<b>Patient Name</b>	Mrs. SANDHAYA	<b>Client Name</b>	Civil Hospital-P	<b>Specimen Received</b>	05/01/2019
<b>Age/Sex</b>	40/F		Gurgaon	<b>Specimen Type</b>	Tissue
<b>Patient ID</b>	011901050105	<b>Client Code</b>	MolQ1681P	<b>Collection Date</b>	05/01/2019
<b>Specimen ID</b>	MOLQ/B-27/19	<b>Ref. Doc</b>	DR AMANDEEP SAHARA	<b>Report Date</b>	08/01/2019

## SURGICAL PATHOLOGY REPORT

### GALL BLADDER.

#### DIAGNOSIS

**CHOLECYSTITIS AND CHOLELITHIASIS.**



#### SPECIMEN

Gall Bladder.

#### GROSS

Received 5x2.8 cm long gall bladder. Cut section shows stones.

#### Microscopy

1. Section examined shows ulcerative mucosa and rokitansky aschoff sinus with fibro collagenous tissue and inflammatory cells.
2. Section also shows lymphoid follicles, hemosiderin laden macrophages.

**Note :** All biopsy specimen will be stored for 15 (fifteen) days, block and slides for 5 (five) years only from the time of receipt at the laboratory. No request ,for any of the above will be entertained after the due date.

#### Reference

- i) Rosai and Ackerman's Surgical Pathology.
- ii) Modern Surgical Pathology.

**Gulshan Yadav, MD**  
Consultant Pathologist