

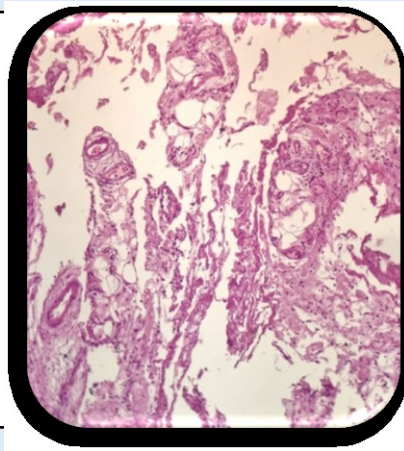
<b>Patient Name</b>	<b>Mrs. POONAM THAKKAR</b>	<b>Client Name</b>	Lifeaid Wellness Centre, Gurgaon	<b>Specimen Received</b>	04/01/2019
<b>Age/Sex</b>	41/F	<b>Client Code</b>	MolQ1476CM	<b>Specimen Type</b>	Tissue
<b>Patient ID</b>	011901040128	<b>Ref. Doc</b>		<b>Collection Date</b>	04/01/2019
<b>Specimen ID</b>	MOLQ/B-19/19			<b>Report Date</b>	07/01/2019

**SURGICAL PATHOLOGY REPORT**

**GALL BLADDER.**

**DIAGNOSIS**

**CHOLECYSTITIS AND CHOLELITHIASIS.**



**SPECIMEN**

Gall Bladder.

**GROSS**

Received 9x4cm long gall bladder. Cut section shows stone.

**Microscopy**

1. Section examined shows ulcerative mucosa and rokitansky aschoff sinus with fibro collagenous tissue and inflammatory cells .

**Note :** All biopsy specimen will be stored for 15 (fifteen) days, block and slides for 5 (five) years only from the time of receipt at the laboratory. No request ,for any of the above will be entertained after the due date.

**Reference**

- i) Rosai and Ackerman's Surgical Pathology.
- ii) Modern Surgical Pathology.

**Gulshan Yadav, MD  
Consultant Pathologist**