

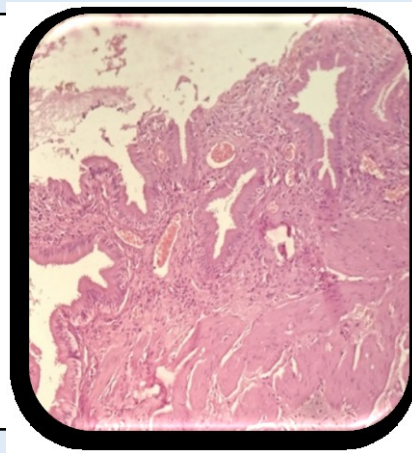
|                     |                                |                    |  |                          |            |
|---------------------|--------------------------------|--------------------|--|--------------------------|------------|
| <b>Patient Name</b> | <b>Mrs. MEHBOOBA INDERKOTE</b> | <b>Client Name</b> | New Unique Diagnostic Center,<br>Jammu & Kashmir | <b>Specimen Received</b> | 03/01/2019 |
| <b>Age/Sex</b>      | 38/F                           | <b>Client Code</b> | MolQ1833P  | <b>Specimen Type</b>     | Tissue     |
| <b>Patient ID</b>   | 011901030285                   | <b>Ref. Doc</b>    |  | <b>Collection Date</b>   | 03/01/2019 |
| <b>Specimen ID</b>  | MOLQ/B-10/19                   |                    |  | <b>Report Date</b>       | 05/01/2019 |

**SURGICAL PATHOLOGY REPORT**

**GALL BLADDER.**

**DIAGNOSIS**

**CHOLECYSTITIS AND CHOLELITHIASIS.**



**SPECIMEN**

Gall Bladder.

**GROSS**

Received 6.2x1.9cm long gall bladder. already cut open with stone.

**Microscopy**

- Section examined shows ulcerative mucosa and rokitansky aschoff sinus with fibro collagenous tissue and inflammatory cells .

**Note :** All biopsy specimen will be stored for 15 (fifteen) days, block and slides for 5 (five) years only from the time of receipt at the laboratory. No request ,for any of the above will be entertained after the due date.

**Reference**

- Rosai and Ackerman's Surgical Pathology.
- Modern Surgical Pathology.

**Gulshan Yadav, MD  
Consultant Pathologist**