

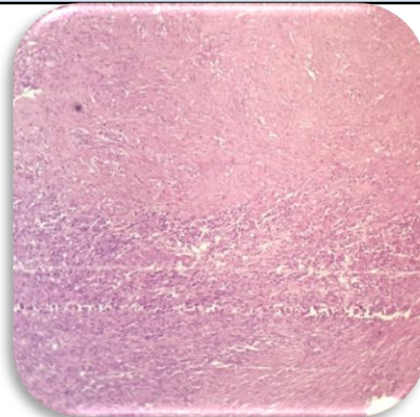
<b>Patient Name</b>	Mr. RAJIV SHARMA	<b>Client Name</b>	Shri Balaji Multispeciality	<b>Specimen Received</b>	21/12/2018
<b>Age/Sex</b>	32/M		Hospital-Gurgaon	<b>Specimen Type</b>	Tissue
<b>Patient ID</b>	011812210147	<b>Client Code</b>	MolQ1269CM	<b>Collection Date</b>	21/12/2018
<b>Specimen ID</b>	MOLQ/B-1452/18	<b>Ref. Doctor</b>		<b>Report Date</b>	25/12/2018

## SURGICAL PATHOLOGY REPORT

### Cysticercosis cyst

#### DIAGNOSIS

**Chronic Granulomatous Reaction ( Parasitic Infestation to ruled out)**



#### SPECIMEN

Cysticercosis cyst

#### GROSS

Received two tissue piece 4x5cm and 4x3.2cm yellowish tissue piece.

#### Microscopy

1. Section examined shows fibrocollagenous tissue mature adipose cells with large number of mononuclear inflammatory cells with non caseating granuloma, muscle bundle.

**Note :** All biopsy specimen will be stored for 15 (fifteen)days, block and slides for 5(five) years only from the time of receipt at the laboratory. No request ,for any of the above ,will be entertained after the due date.

#### Reference

- i) Rosai and Ackerman's Surgical Pathology.
- ii) Modern Surgical Pathology.

**Gulshan Yadav, MD  
Consultant Pathologist**