

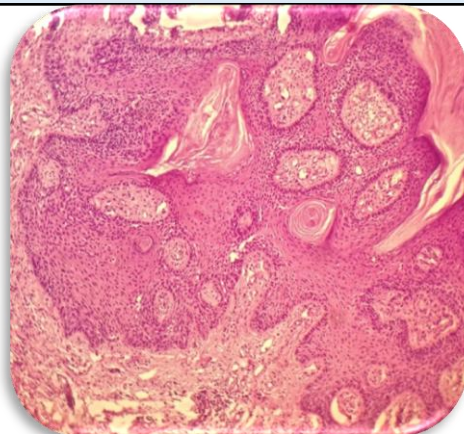
Patient Name	Mrs. JANA BANU-7218	Client Name	Patients Care Clinical	Specimen Received	01/01/2019
Age/Sex	60 Years/Female		Laboratory, Jammu & Kashmir	Specimen Type	Tissue
Patient ID	011901010026	Client Code	MolQ1839P	Collection Date	01/01/2019
Specimen ID	MOLQ/B-02/19	Ref. Doctor		Report Date	05/01/2019

SURGICAL PATHOLOGY REPORT

Squamous Papilloma

DIAGNOSIS

SQUAMOUS PAPILLOMA WITH CHRONIC INFLAMMATION.



SPECIMEN

Squamous Papilloma

GROSS

Received 2x3 cm greyish white tissue piece with skin. Skin shows two proliferative growth, well circumscribed measuring 1x1.5, 1.5 x 1.5 cms.

Microscopy

- Section examined shows squamous lining epithelium with hyperplasia and round to oval nucleus and marker hyperkeratosis, parakeratosis. Deeper tissue shows fibrocollagenous tissue, heavy mononuclear inflammatory cells.

Note : All biopsy specimen will be stored for 15 (fifteen)days, block and slides for 5(five) years only from the time of receipt at the laboratory. No request ,for any of the above ,will be entertained after the due date.

Reference

- Rosai and Ackerman's Surgical Pathology.
- Modern Surgical Pathology.

Gulshan Yadav, MD
Consultant Pathologist