

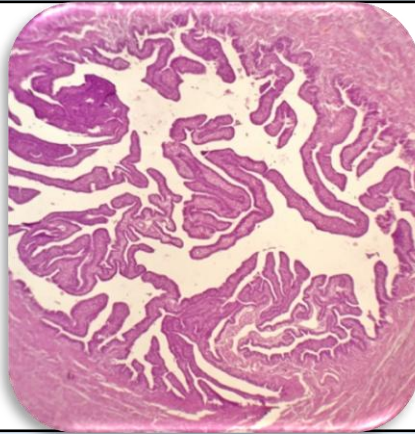
<b>Patient Name</b>	Mrs. PRIYANKA-22365	<b>Client Name</b>	Pushpanjali Hospital	<b>Specimen Received</b>	29/12/2018
<b>Age/Sex</b>	25 YRS/F		(Rewari)	<b>Specimen Type</b>	Tissue
<b>Patient ID</b>	011812290165	<b>Client Code</b>	MolQ1789CM	<b>Collection Date</b>	29/12/2018
<b>Specimen ID</b>	MOLQ/B-1511/18-1	<b>Ref. Doctor</b>	DR.KIRAN	<b>Report Date</b>	05/01/2019

## SURGICAL PATHOLOGY REPORT

Left Tube with Ectopic Pregnancy

### DIAGNOSIS

**KINDLY, CO-RELATE WITH CLINICAL, RADIOLOGICAL AND B-hcg FINDINGS.**



#### **SPECIMEN**

Left Tube with Ectopic Pregnancy

#### **GROSS**

Received 7x0.5 cm tube.

#### **Microscopy**

- Section examined shows tubal lining epithelium having columnar cells with round to oval nucleus. Lumen shows only RBCs. No trophoblastic cells. No decidual cells seen in sample received.

**Note :** All biopsy specimen will be stored for 15 (fifteen) days, block and slides for 5 (five) years only from the time of receipt at the laboratory. No request ,for any of the above, will be entertained after the due date.

#### **Reference**

- Rosai and Ackerman's Surgical Pathology.
- Modern Surgical Pathology.

**Gulshan Yadav, MD  
Consultant Pathologist**