

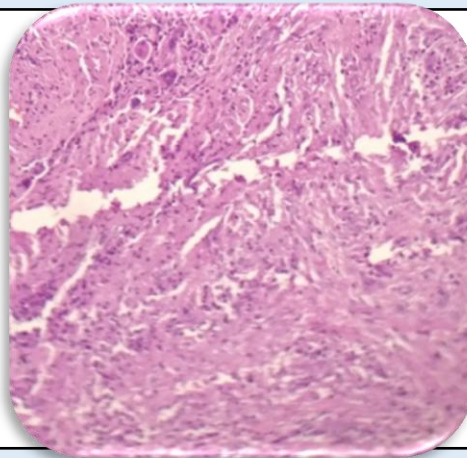
<b>Patient Name</b>	Mrs. MEENA	<b>Client Name</b>	Civil Hopital, Sector-10, Gurgaon	<b>Specimen Received</b>	29/12/2018
<b>Age/Sex</b>	18/F	<b>Client Code</b>		<b>Specimen Type</b>	Tissue
<b>Patient ID</b>	011812290120	<b>Ref. Doctor</b>		<b>Collection Date</b>	29/12/2018
<b>Specimen ID</b>	MOLQ/B-1513-18			<b>Report Date</b>	05/01/2019

## SURGICAL PATHOLOGY REPORT

Right Elbow

### DIAGNOSIS

**INFECTIVE LESION**



#### SPECIMEN

Right Elbow

#### GROSSING

Received 0.5x1 cm greyish white tissue piece.

#### Microscopy

- Section examined shows squamous epithelial lining with round to oval nucleus. Deeper tissue shows fibrocollagenous tissue, blood vessels and heavy inflammatory cells (Polymorphs, Lymphocytes and plasmacytoid cells).

**Note :** All biopsy specimen will be stored for 15 (fifteen) days, block and slides for 5 (five) years only from the time of receipt at the laboratory. No request for any of the above will be entertained after the due date.

#### Reference

- Rosai and Ackerman's Surgical Pathology.
- Modern Surgical Pathology

**Gulshan Yadav, MD**  
Consultant Pathologist