

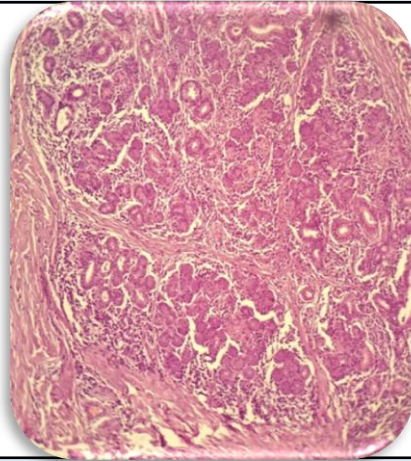
Patient Name	Mr. SUBHASH CHAND	Client Name	Life Care Path Lab,	Specimen Received	31/12/2018
Age/Sex	65 Years/Male		Tauru	Specimen Type	Tissue
Patient ID	011812310181	Client Code	MolQ1518P	Collection Date	31/12/2018
Specimen ID	MOLQ/B-1526/18	Ref. Doctor		Report Date	04/01/2019

SURGICAL PATHOLOGY REPORT

Submandibular Gland

DIAGNOSIS

CHRONIC SIALEDENITIS



SPECIMEN

Submandibular Gland

GROSS

Received 4x3 cm greyish white tissue piece.

Microscopy

- Section examined shows salivary ducts with glands lined by cuboidal lining epithelium with round to oval nucleus, surrounded by fibro collagenous tissue, mononuclear inflammatory cells (Lymphocytes, plasma cells)
- No malignant cells and no granuloma seen.

Note : All biopsy specimen will be stored for 15 (fifteen)days, block and slides for 5(five) years only from the time of receipt at the laboratory. No request ,for any of the above, will be entertained after the due date.

Reference

- Rosai and Ackerman's Surgical Pathology.
- Modern Surgical Pathology.

Tina Bhardwaj, MDS
Consultant Oral Histopathologist

Gulshan Yadav, MD
Consultant Pathologist