

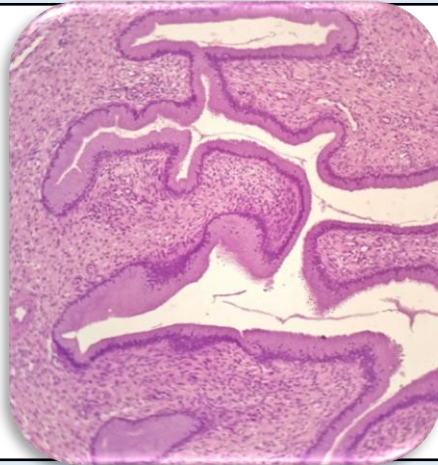
Patient Name	Mrs. MUKESH-22387	Client Name	Pushpanjali Hospital	Specimen Received	31/12/2018
Age/Sex	45 Years/Female		(Rewari)	Specimen Type	Tissue
Patient ID	011812310146	Client Code	MolQ1789CM	Collection Date	31/12/2018
Specimen ID	MOLQ/B-1529/18	Ref. Doctor	Dr Kiran	Report Date	04/01/2019

SURGICAL PATHOLOGY REPORT

Cervical Polyp

DIAGNOSIS

CERVICAL POLYP



SPECIMEN

Cervical Polyp

GROSS

Received 4x2.1 cm long greyish white tissue piece.

Microscopy

1. Section examined shows squamous epithelial lining with endocervical glands lined by columnar lining epithelium, round to oval nucleus with large number of inflammatory cells (Lymphocytes and polymorphs)
2. No malignant and no granuloma seen.

Note : All biopsy specimen will be stored for 15 (fifteen) days, block and slides for 5 (five) years only from the time of receipt at the laboratory. No request, for any of the above, will be entertained after the due date.

Reference

- i) Rosai and Ackerman's Surgical Pathology.
- ii) Modern Surgical Pathology.

Gulshan Yadav, MD
Consultant Pathologist