

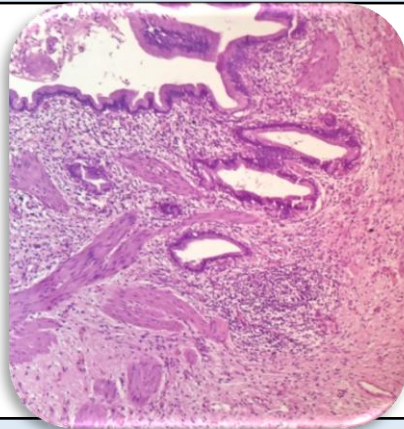
Patient Name	Mr. SURENDER-2180	Client Name	Pushpanjali Hospital	Specimen Received	31/12/2018
Age/Sex	58 Years/Male		(Rewari)	Specimen Type	Tissue
Patient ID	011812310142	Client Code	MolQ1789CM	Collection Date	31/12/2018
Specimen ID	MOLQ/B-1528/18	Ref. Doctor	DR.KULDEEP	Report Date	04/01/2019

SURGICAL PATHOLOGY REPORT

GALL BLADDER.

DIAGNOSIS

CHOLECYSTITIS AND CHOLELITHIASIS.



SPECIMEN

Gall Bladder.

GROSS

Received 6.5 x 2.8 cm long gall bladder. Cut section shows stones.

Microscopy

1. Section examined shows ulcerative mucosa and rokitansky aschoff sinus with fibrocollagenous tissue and inflammatory cells .

Note : All biopsy specimen will be stored for 15 (fifteen)days, block and slides for 5(five) years only from the time of receipt at the laboratory. No request ,for any of the above ,will be entertained after the due date.

Reference

- i) Rosai and Ackerman's Surgical Pathology.
- ii) Modern Surgical Pathology.

Gulshan Yadav, MD
Consultant Pathologist