

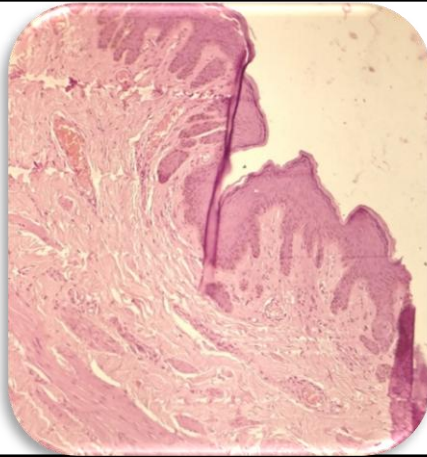
Patient Name	Mr. OMPAL SINGH	Client Name	Bharat Ultrasound,	Specimen Received	31/12/2018
Age/Sex	59/M		NUH	Specimen Type	Tissue
Patient ID	011812310101	Client Code	MolQ1757P	Collection Date	31/12/2018
Specimen ID	MOLQ/B-1525/18	Ref. Doctor		Report Date	04/01/2019

SURGICAL PATHOLOGY REPORT

Sebaceous Cyst

DIAGNOSIS

SEBACEOUS CYST



SPECIMEN

Sebaceous Cyst

GROSS

Received multiple greyish white tissue piece measuring 2x3 and 1x1 cm.

Microscopy

1. Section examined shows squamous epithelial lining with round nucleus. Deeper tissue shows fibrocollagenous tissue, keratin flakes with inflammatory cells and granular necrosis.
2. No malignant cells and no granuloma seen.

Note : All biopsy specimen will be stored for 15 (fifteen) days, block and slides for 5 (five) years of receipt of the laboratory. No request, for any of the above, will be entertained after the due date.

Reference

- i) Rosai and Ackerman's Surgical Pathology.
- ii) Modern Surgical Pathology.

Gulshan Yadav
Gulshan Yadav, MD
Consultant Pathologist