

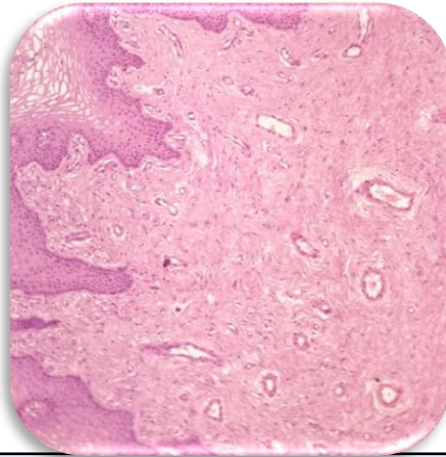
Patient Name	Mrs. ARCHNA TIWARI	Client Name	Yadav Lab-B	Specimen Received	30/12/2018
Age/Sex	34 Years/Female			Specimen Type	Tissue
Patient ID	011812300138	Client Code	MOLQ1095CM	Collection Date	30/12/2018
Specimen ID	MOLQ/B-1519/18	Ref. Doctor		Report Date	04/01/2019

SURGICAL PATHOLOGY REPORT

Vaginal Cyst (Right)

DIAGNOSIS

BENIGN CYSTIC LESION



SPECIMEN

Vaginal Cyst (Right)

GROSS

Received 4x3 cm greyish white tissue piece. Cut section shows mucoid material.


Microscopy

1. Section examined shows squamous epithelial lining with round nucleus and hyperkeratosis. Deeper tissue shows fibrocollagenous tissue and blood vessels.
2. No malignant cells and no granuloma seen.

Note : All biopsy specimen will be stored for 15 (fifteen) days, block and slides for 5 (five) years only from the time of receipt at the laboratory. No request, for any of the above, will be entertained after the due date.

Reference

- i) Rosai and Ackerman's Surgical Pathology.
- ii) Modern Surgical Pathology.



Gulshan Yadav, MD
Consultant Pathologist