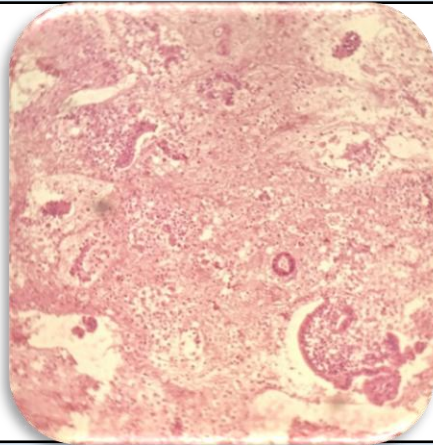


Patient Name	Mrs. POONAM W/O AATMA RAM	Client Name	Health Medicos, Rohtak	Specimen Received	30/12/2018
Age/Sex	31 Years/Female	Client Code	MolQ1394CM	Specimen Type	Tissue
Patient ID	011812300134	Ref. Doctor		Collection Date	30/12/2018
Specimen ID	MOLQ/B-1518/18			Report Date	03/01/2019

SURGICAL PATHOLOGY REPORT

ENDOMETRIUM

PROLIFERATIVE PHASE .



SPECIMEN

Endometrium

GROSS

Received multiple greyish white tissue piece.

Microscopy

- Section examined shows small endometrial glands with cuboidal to columnar lining epithelium with round to oval nucleus. Stroma shows mononuclear inflammatory cells.
- No malignant cells and no granuloma seen.

Note : All biopsy specimen will be stored for 15 (fifteen) days, block and slides for 5 (five) years only from the time of receipt at the laboratory. No request for any of the above, will be entertained after the due date.

Reference

- Rosai and Ackerman's Surgical Pathology.
- Modern Surgical Pathology.

Gulshan Yadav, MD
Consultant Pathologist