

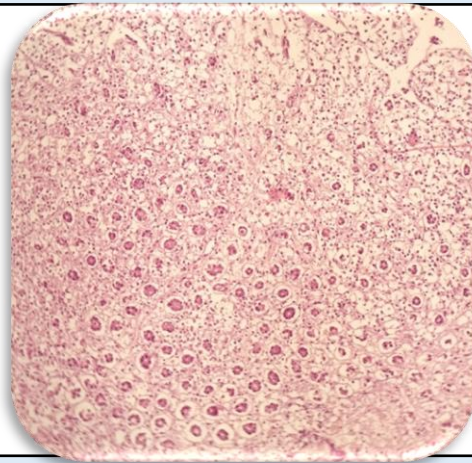
Patient Name	Mr. YOGESH-22355	Client Name	Pushpanjali Hospital	Specimen Received	29/12/2018
Age/Sex	33/M		(Rewari)	Specimen Type	Tissue
Patient ID	011812290169	Client Code	MolQ1789CM	Collection Date	29/12/2018
Specimen ID	MOLQ/B-1517/18	Ref. Doctor	DR.KAMAL	Report Date	03/01/2019

SURGICAL PATHOLOGY REPORT

Duodenal Ulcer

DIAGNOSIS

CHRONIC INFLAMMATION



SPECIMEN

Duodenal Ulcer

GROSS

Received multiple tiny greyish white tissue piece.

Microscopy

1. Section examined shows autolytic changes with sub mucosal glands having round nucleus with inflammatory cells (lymphocyte, polymorphs).
2. No malignant cells and no granuloma seen in the biopsy received.

Note : All biopsy specimen will be stored for 15 (fifteen)days, block and slides for 5(five) years only from the time of receipt at the laboratory. No request ,for any of the above ,will be entertained after the due date.

Reference

- i) Rosai and Ackerman's Surgical Pathology.
- ii) Modern Surgical Pathology.

Gulshan Yadav, MD
Consultant Pathologist