

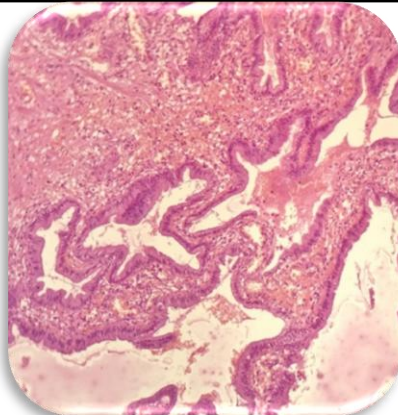
<b>Patient Name</b>	Mrs. RAJNI	<b>Client Name</b>	Civil Hospital-P	<b>Specimen Received</b>	28/12/2018
<b>Age/Sex</b>	35/F		Gurgaon	<b>Specimen Type</b>	Tissue
<b>Patient ID</b>	011812280191	<b>Client Code</b>	MolQ1681P	<b>Collection Date</b>	28/12/2018
<b>Specimen ID</b>	MOLQ/B-1497/18	<b>Ref. Doc</b>	DR AMANDEEP SAHARAN	<b>Report Date</b>	01/01/2019

## SURGICAL PATHOLOGY REPORT

### GALL BLADDER.

#### DIAGNOSIS

**CHOLECYSTITIS AND CHOLELITHIASIS.**



#### **SPECIMEN**

Gall Bladder.

#### **GROSS**

Received 6.5x3.2cm long gall bladder.

#### **Microscopy**

1. Section examined shows ulcerative mucosa and Rokitansky-Aschoff sinuses with fibro collagenous tissue and inflammatory cells .

**Note :** All biopsy specimen will be stored for 15 (fifteen) days, block and slides for 5 (five) years only from the time of receipt at the laboratory. No request ,for any of the above will be entertained after the due date.

#### **Reference**

- i) Rosai and Ackerman's Surgical Pathology.
- ii) Modern Surgical Pathology.

**Gulshan Yadav, MD  
Consultant Pathologist**