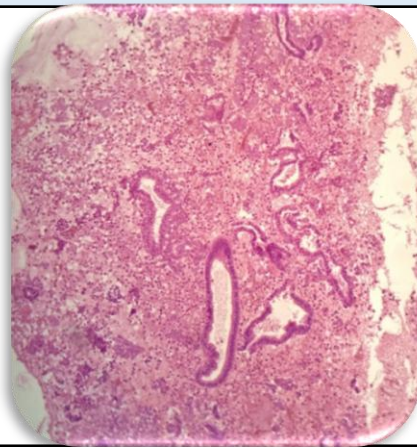


<b>Patient Name</b>	Mrs. SEEMA W/O SUMIT	<b>Client Name</b>	Health Medicos,	<b>Specimen Received</b>	27/12/2018
<b>Age/Sex</b>	23/F		Rohtak	<b>Specimen Type</b>	Tissue
<b>Patient ID</b>	011812270255	<b>Client Code</b>	MolQ1394CM	<b>Collection Date</b>	27/12/2018
<b>Specimen ID</b>	MOLQ/B-1496/18	<b>Ref. Doctor</b>		<b>Report Date</b>	31/12/2018

## SURGICAL PATHOLOGY REPORT

### ENDOMETRIUM

#### PROLIFERATIVE PHASE .



#### SPECIMEN

Endometrium

#### GROSS

Received multiple greyish white tissue piece.

#### Microscopy

1. Section examined shows small endometrial glands, cuboidal lining epithelium with round to oval nucleus.
2. Stroma shows mononuclear inflammatory cells.
3. No malignant cells and no granuloma seen.

**Note :** All biopsy specimen will be stored for 15 (fifteen) days, block and slides for 5 (five) years only from the time of receipt at the laboratory. No request for any of the above, will be entertained after the due date.

#### Reference

- i) Rosai and Ackerman's Surgical Pathology.
- ii) Modern Surgical Pathology.

**Gulshan Yadav, MD**  
Consultant Pathologist