

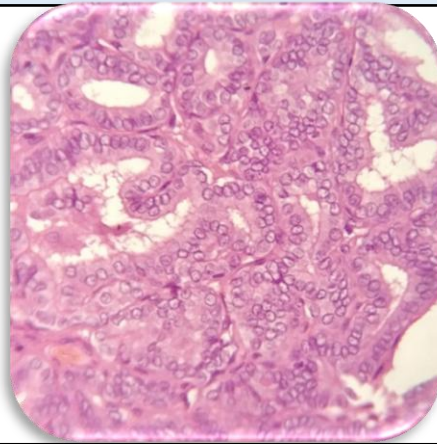
Patient Name	Mrs. RAMITA	Client Name	Civil Hospital-P, Gurgaon	Specimen Received	26/12/2018
Age/Sex	35/F	Client Code		Specimen Type	Tissue
Patient ID	011812260185	Ref. Doctor	DR SAURABH DESWAL	Collection Date	26/12/2018
Specimen ID	MOLQ/B-1488-18			Report Date	29/12/2018

SURGICAL PATHOLOGY REPORT

Cervical Lymph Nodes

DIAGNOSIS

METASTATIC PAPILLARY CARCINOMA OF THYROID



SPECIMEN

Cervical Lymph Nodes

GROSSING

Received 2x3.1 cm lymph node.

Microscopy

- Section examined shows lymph node with presence of numerous true papillae with complex, branching which are randomly oriented with a central fibrovascular core, filled with colloid and lined by single to stratified lining of cuboidal cells intermixed with lymphoid follicles.
- Cuboidal cells shows nuclear features consisting of ground glass (optically clear) nuclei, nuclear grooves and scanty mitosis.
- Presence of Psammoma bodies in the subcapsular area of the lymph node.

Note : All biopsy specimen will be stored for 15 (fifteen) days, block and slides for 5 (five) years only from the time of receipt at the laboratory. No request for any of the above will be entertained after the due date.

Reference

- Rosai and Ackerman's Surgical Pathology.
- Modern Surgical Pathology

Gulshan Yadav, MD
Consultant Pathologist