

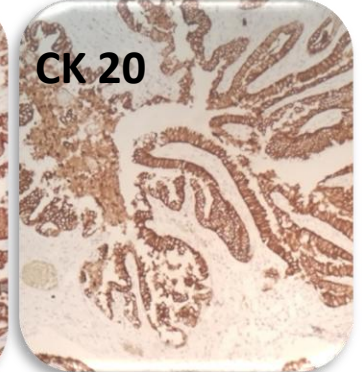
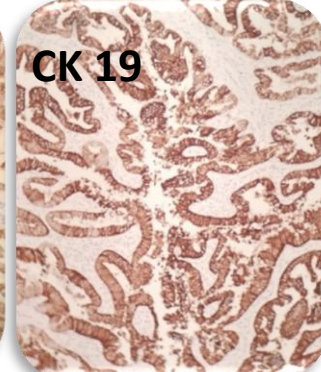
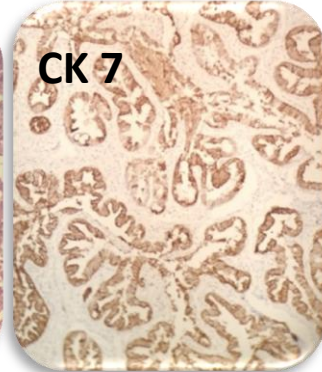
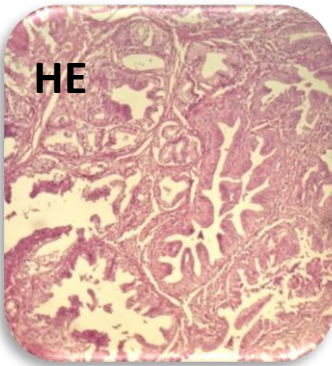
Patient Name	Mrs. Raja	Client Name	New Unique Diagnostic Center,	Specimen Received	20/12/2018
Age/Sex	/F		Jammu & Kashmir	Specimen Type	Tissue
Patient ID	011812200082	Client Code		Collection Date	20/12/2018
Specimen ID	MOLQ/IHC-45/12/2018	Ref. Doctor		Report Date	29/12/2018

SURGICAL PATHOLOGY REPORT

Case of Well Differentiated Adenocarcinoma (Intestinal Type)- Gall Bladder

DIAGNOSIS

Cytokeratin 7- Positive
Cytokeratin 19- Positive
Cytokeratin 20- Positive



Microscopic Findings:

Cytokeratin 7 (CK 7)

% Cells immunoreactive - 80% Intensity- +++

Internal control-Positive

Interpretation-Positive

Cytokeratin 19 (CK 19)

% Cells immunoreactive - 80%

Intensity- +++

Internal control-Positive

Interpretation-Positive

Cytokeratin 20 (CK 20)

% Cells immunoreactive - 80%

Intensity- +++

Internal control-Positive

Interpretation-Positive

SPECIMEN

Case of Well Differentiated Adenocarcinoma
(Intestinal Type)- Gall Bladder

Gulshan Yadav, MD
Consultant Pathologist

Reference

- i) Rosai and Ackerman's Surgical Pathology.
- ii) Modern Surgical Pathology.