

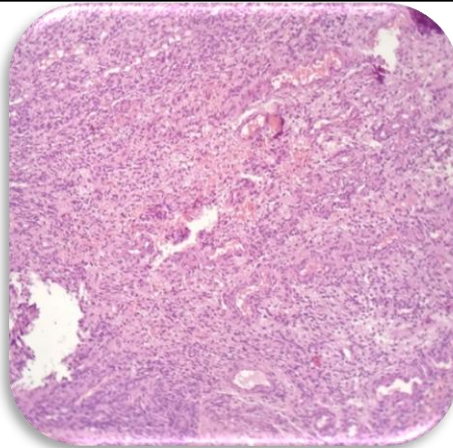
Patient Name	Mrs. PINKI	Client Name	Vedic Hospital,	Specimen Received	23/12/2018
Age/Sex	23 Years/Female		Gurgaon	Specimen Type	Tissue
Patient ID	011812230066	Client Code	MolQ1492CM	Collection Date	23/12/2018
Specimen ID	MOLQ/B-1459/18	Ref. Doctor		Report Date	26/12/2018

SURGICAL PATHOLOGY REPORT

Haemorrhagic ovary

DIAGNOSIS

Haemorrhagic cyst



SPECIMEN

Haemorrhagic ovary

GROSS

Received 4x2cm greyish white tissue piece.

Microscopy

1. Section examined shows ovarian tissue, stromal cells with large number of blood vessels.
2. No malignant and no granuloma seen.

Note : All biopsy specimen will be stored for 15 (fifteen) days, block and slides for 5 (five) years of receipt of the laboratory. No request, for any of the above, will be entertained after the due date.

Reference

- i) Rosai and Ackerman's Surgical Pathology.
- ii) Modern Surgical Pathology.

Gulshan
Gulshan Yadav, MD
Consultant Pathologist