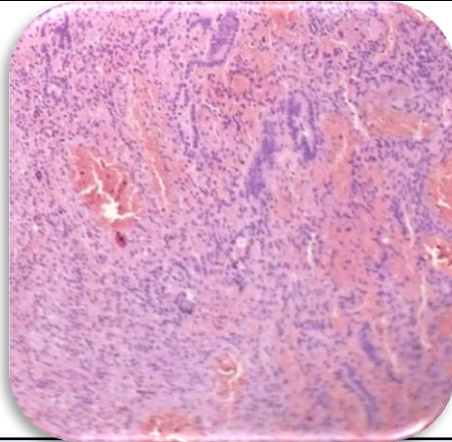


Patient Name	Mrs. BALESH	Client Name	Kamal Hospital and Maternity Centre	Specimen Received	23/12/2018
Age/Sex	50 Years/Female			Specimen Type	Tissue
Patient ID	011812230028	Client Code	MolQ1329CM	Collection Date	23/12/2018
Specimen ID	MOLQ/B-1460/18			Report Date	2/12/2018

SURGICAL PATHOLOGY REPORT

ENDOMETRIUM

BLEEDING ENDOMETRIUM WITH DISORDERED PROLIFERATIVE PHASE



SPECIMEN

Endometrium

GROSS

Received multiple greyish white tissue piece.

Microscopy

- Section examined shows tortuous and small endometrial glands having columnar lining epithelium with round to oval nucleus with vacuoles in few glands. Stroma shows mononuclear inflammatory cells.
- No malignant and no granuloma seen.

Note : All biopsy specimen will be stored for 15 (fifteen) days, block and slides for 5 (five) years only from the time of receipt at the laboratory. No request for any of the above, will be entertained after the due date.

Reference

- Rosai and Ackerman's Surgical Pathology.
- Modern Surgical Pathology.

Gulshan Yadav, MD
Consultant Pathologist