

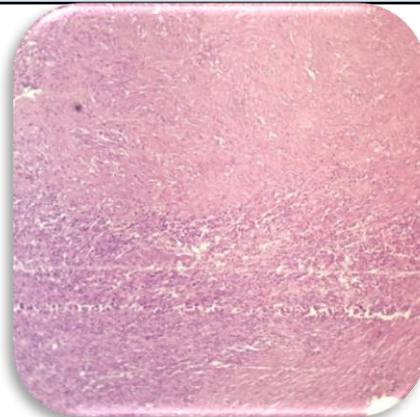
Patient Name	Mr. RAJIV SHARMA	Client Name	Shri Balaji Multispeciality	Specimen Received	21/12/2018
Age/Sex	32/F		Hospital-Gurgaon	Specimen Type	Tissue
Patient ID	011812210147	Client Code	MolQ1269CM	Collection Date	21/12/2018
Specimen ID	MOLQ/B-1452/18	Ref. Doctor		Report Date	25/12/2018

SURGICAL PATHOLOGY REPORT

Cysticercosis cyst

DIAGNOSIS

Chronic Granulomatous Reaction (Parasitic Infestation to ruled out)



SPECIMEN

Cysticercosis cyst

GROSS

Received two tissue piece 4x5cm and 4x3.2cm yellowish tissue piece.

Microscopy

1. Section examined shows fibrocollagenous tissue mature adipose cells with large number of mononuclear inflammatory cells with non caseating granuloma, muscle bundle.

Note : All biopsy specimen will be stored for 15 (fifteen)days, block and slides for 5(five) years only from the time of receipt at the laboratory. No request ,for any of the above ,will be entertained after the due date.

Reference

- i) Rosai and Ackerman's Surgical Pathology.
- ii) Modern Surgical Pathology.

**Gulshan Yadav, MD
Consultant Pathologist**