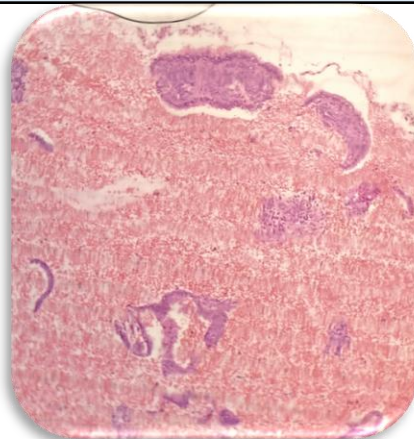


Patient Name	Mrs. MAYA DEVI-21628	Client Name	Pushpanjali Hospital	Specimen Received	20/12/2018
Age/Sex	49 Years/Female		(Rewari)	Specimen Type	Tissue
Patient ID	011812200261	Client Code	MolQ1789CM	Collection Date	20/12/2018
Specimen ID	MOLQ/B-1448/18	Ref. Doc	DR.KIRAN	Report Date	24/12/2018

SURGICAL PATHOLOGY REPORT

ENDOMETRIUM

BLEEDING ENDOMETRIUM WITH PROLIFERATIVE PHASE



SPECIMEN

Endometrium

GROSS

Received multiple greyish white tissue piece.

Microscopy

- Section examined shows small endometrial glands having cuboidal lining epithelium with round to oval nucleus with large number of RBCs and inflammatory cells.
- No granuloma and no malignant cells seen.

Note : All biopsy specimen will be stored for 15 (fifteen) days, block and slides for 5 (five) years only from the time of receipt at the laboratory. No request for any of the above, will be entertained after the due date.

Reference

- Rosai and Ackerman's Surgical Pathology.
- Modern Surgical Pathology.

Gulshan Yadav, MD
Consultant Pathologist