

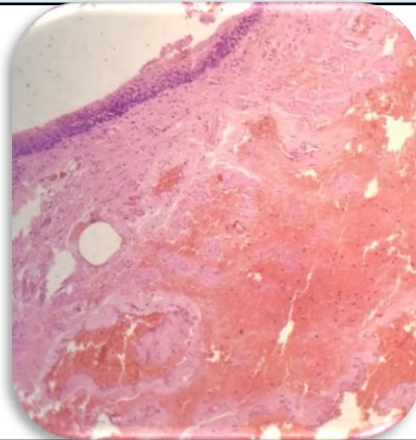
Patient Name	Mr. SANJEEV KUMAR-21828	Client Name	Pushpanjali Hospital (Rewari)	Specimen Received	20/12/2018
Age/Sex	31/M	Client Code	MolQ1789CM	Specimen Type	Tissue
Patient ID	011812200260	Ref. Doctor	DR.KULDEEP	Collection Date	20/12/2018
Specimen ID	MOLQ/B-1447/18			Report Date	24/12/2018

SURGICAL PATHOLOGY REPORT

HEMORRHOIDS

DIAGNOSIS

HEMORRHOIDS



SPECIMEN

Hemorrhoids

GROSS

Received 2 x 2.5 cm long greyish white tissue piece

Microscopy

- Section examined shows submucosal glands, fibro collagenous tissue with blood vessels.No granuloma and no malignant cells seen.

Note : All biopsy specimen will be stored for 15 (fifteen)days, block and slides for 5(five) years only from the time of receipt at the laboratory. No request ,for any of the above ,will be entertained after the due date.

Reference

- Rosai and Ackerman's Surgical Pathology.
- Modern Surgical Pathology.

Gulshan Yadav, MD
Consultant Pathologist