

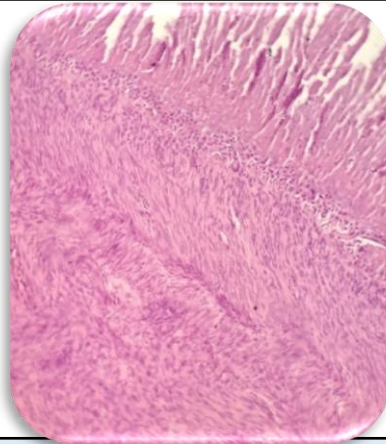
<b>Patient Name</b>	Mrs. SAJIYA	<b>Client Name</b>	Murad Hospital, Nuh	<b>Specimen Received</b>	19/12/2018
<b>Age/Sex</b>	28/F	<b>Client Code</b>	MolQ1830P	<b>Specimen Type</b>	Tissue
<b>Patient ID</b>	011812190169	<b>Ref. Doctor</b>	MURAD HOSPITAL	<b>Collection Date</b>	19/12/2018
<b>Specimen ID</b>	MOLQ/B-1433-18			<b>Report Date</b>	24/12/2018

## SURGICAL PATHOLOGY REPORT

Complex Solid Cystic Mass Lesion (Left Adnexa)

### DIAGNOSIS

**MUCINOUS BORDERLINE TUMOR OF LEFT OVARY**



#### SPECIMEN

Complex Solid Cystic Mass Lesion (Left Adnexa)

#### GROSSING

Received 11x8 cm ovarian cyst, cut section shows mucoid material with tube.

#### Microscopy

1. Section examined shows cystic lumen filled with mucoid material and is lined by characteristic epithelial lining composed of picket fence appearance resembling intestinal like epithelium.
2. Stroma is composed of hypercellular with few inflammatory cells.
3. There is no stromal invasion.

**Note :** All biopsy specimen will be stored for 15 (fifteen) days, block and slides for 5 (five) years only from the time of receipt at the laboratory. No request for any of the above will be entertained after the due date.

#### Reference

- i) Rosai and Ackerman's Surgical Pathology.
- ii) Modern Surgical Pathology
- iii) Shafers, 7<sup>th</sup> Edition

**Gulshan Yadav, MD**  
Consultant Pathologist