

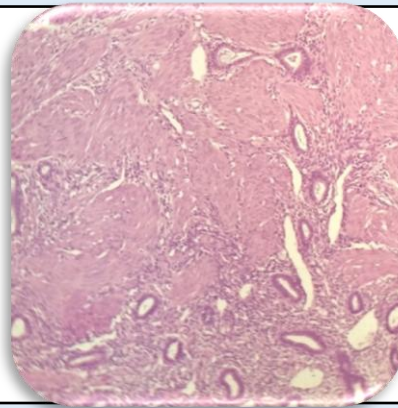
<b>Patient Name</b>	<b>Mrs. SAPNA JAIN</b>	<b>Client Name</b>	SBS Diagnostic Centre	<b>Specimen Received</b>	14/12/2018
<b>Age/Sex</b>	47 Years/Female		Gurgaon	<b>Specimen Type</b>	Tissue
<b>Patient ID</b>	011812140166	<b>Client Code</b>	MolQ1325CM	<b>Collection Date</b>	14/12/2018
<b>Specimen ID</b>	MOLQ/B-1394/18 (Container 2)	<b>Ref. Doctor</b>		<b>Report Date</b>	17/12/2018

## SURGICAL PATHOLOGY REPORT

Endometrial curetting.

### DIAGNOSIS

**KINDLY, CO-RELATE CLINICALLY AND RADIOLOGICALLY**



#### SPECIMEN

Endometrial curetting.

#### GROSS

Received multiple greyish white tissue piece.

#### Microscopy

- Section examined shows scanty endometrial tissue with RBCs with inflammatory cells and few stromal cells. No endometrial gland seen in sample received .

**Note :** All biopsy specimen will be stored for 15 (fifteen)days, block and slides for 5(five) years only from the time of receipt at the laboratory. No request ,for any of the above ,will be entertained after the due date.

#### Reference

- Rosai and Ackerman's Surgical Pathology.
- Modern Surgical Pathology.

**Gulshan Yadav, MD**  
Consultant Pathologist