

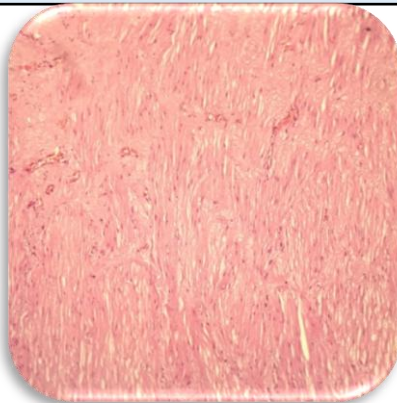
<b>Patient Name</b>	<b>Mr. SANDEEP-21665</b>	<b>Client Name</b>	Pushpanjali Hospital	<b>Specimen Received</b>	19/12/2018
<b>Age/Sex</b>	25Years/Female		(Rewari)	<b>Specimen Type</b>	Tissue
<b>Patient ID</b>	011812190242	<b>Client Code</b>	MolQ1789CM	<b>Collection Date</b>	19/12/2018
<b>Specimen ID</b>	MOLQ/B-1437/18	<b>Ref. Doctor</b>	DR KULDEEP	<b>Report Date</b>	21/12/2018

## SURGICAL PATHOLOGY REPORT

### Right great saphenous vein.

#### DIAGNOSIS

**Varicose veins.**



#### SPECIMEN

Right great saphenous vein.

#### GROSS

Received 11x1 and 8x1cm vein received.

#### Microscopy

1. Section examined shows fibro collagenous tissue with dilated lumen with RBCs.
2. No malignant cells and granuloma seen.

**Note :** All biopsy specimen will be stored for 15 (fifteen) days, block and slides for 5 (five) years only from the time of receipt at the laboratory. No request ,for any of the above ,will be entertained after the due date.

#### Reference

- i) Rosai and Ackerman's Surgical Pathology.
- ii) Modern Surgical Pathology.

**Gulshan Yadav, MD**  
Consultant Pathologist