

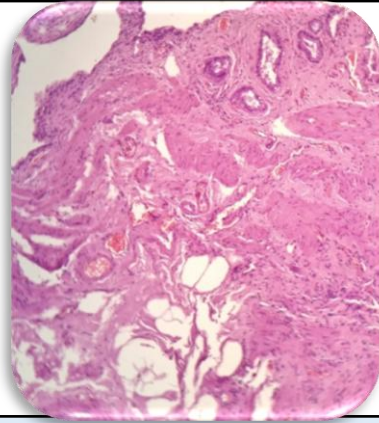
Patient Name	Mrs. BHATERI-21644	Client Name	Pushpanjali Hospital	Specimen Received	19/12/2018
Age/Sex	68 Years/Female		(Rewari)	Specimen Type	Tissue
Patient ID	011812190241	Client Code	MolQ1789CM	Collection Date	19/12/2018
Specimen ID	MOLQ/B-1438/18	Ref. Doctor	DR KULDEEP	Report Date	21/12/2018

SURGICAL PATHOLOGY REPORT

GALL BLADDER.

DIAGNOSIS

CHOLECYSTITIS AND CHOLELITHIASIS.



SPECIMEN

Gall Bladder.

GROSS

Received 6.2x3.8 cm long gall bladder already cut open with stone.

Microscopy

1. Section examined shows ulcerative mucosa and rokitansky aschoff sinus with fibrocollagenous tissue and inflammatory cells .

Note : All biopsy specimen will be stored for 15 (fifteen)days, block and slides for 5(five) years only from the time of receipt at the laboratory. No request ,for any of the above ,will be entertained after the due date.

Reference

- i) Rosai and Ackerman's Surgical Pathology.
- ii) Modern Surgical Pathology.

**Gulshan Yadav, MD
Consultant Pathologist**