

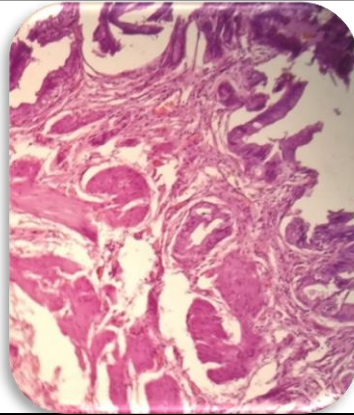
<b>Patient Name</b>	<b>Mr. JASWANT-21737</b>	<b>Client Name</b>	Pushpanjali Hospital (Rewari)	<b>Specimen Received</b>	19/12/2018
<b>Age/Sex</b>	70 Years/Male	<b>Client Code</b>	MolQ1789CM	<b>Specimen Type</b>	Tissue
<b>Patient ID</b>	011812190233	<b>Ref. Doctor</b>	DR KULDEEP	<b>Collection Date</b>	19/12/2018
<b>Specimen ID</b>	MOLQ/B-1441/18			<b>Report Date</b>	21/12/2018

## SURGICAL PATHOLOGY REPORT

### Gall bladder

#### DIAGNOSIS

**CHOLECYSTITIS AND CHOLELITHIASIS.**



#### SPECIMEN

Gall bladder

#### GROSS

Received 7.2x2.8cm long gall bladder. Cut section shows stone.

#### Microscopy

1. Section examined shows ulcerative mucosa and Rokitansky-Aschoff sinuses with fibrocollagenous tissue and inflammatory cells.

**Note :** All biopsy specimen will be stored for 15 (fifteen) days, block and slides for 5 (five) years only from the time of receipt at the laboratory. No request, for any of the above, will be entertained after the due date.

#### Reference

- i) Rosai and Ackerman's Surgical Pathology.
- ii) Modern Surgical Pathology.

**Gulshan Yadav, MD  
Consultant Pathologist**