

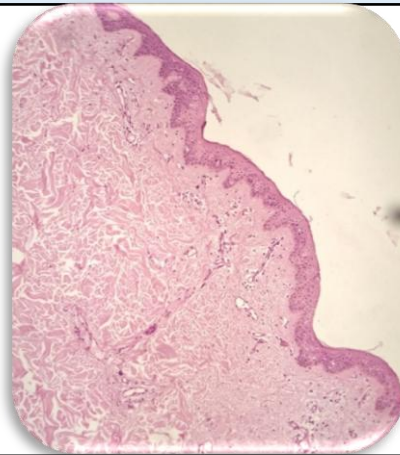
<b>Patient Name</b>	<b>Mrs. PREETI GUPTA</b>	<b>Client Name</b>	Lifeaid Wellness Centre	<b>Specimen Received</b>	17/12/2018
<b>Age/Sex</b>	43 Years/Female		Gurgaon	<b>Specimen Type</b>	Tissue
<b>Patient ID</b>	011812170236	<b>Client Code</b>	MolQ1476CM	<b>Collection Date</b>	17/12/2018
<b>Specimen ID</b>	MOLQ/B-1414/18	<b>Ref. Doctor</b>		<b>Report Date</b>	20/12/2018

## SURGICAL PATHOLOGY REPORT

### Sebaceous Cyst

#### DIAGNOSIS

#### SEBACEOUS CYST



#### SPECIMEN

Sebaceous Cyst

#### GROSS

Received autolyzed two greyish white tissue piece 3x2, 2x1 cms.

#### Microscopy

- Section examined shows squamous lining epithelium with hyperkeratosis, parakeratosis, keratin flakes and mature adipose cells.

**Note :** All biopsy specimen will be stored for 15 (fifteen)days, block and slides for 5(five) years only from the time of receipt at the laboratory. No request ,for any of the above ,will be entertained after the due date.

#### Reference

- Rosai and Ackerman's Surgical Pathology.
- Modern Surgical Pathology.

**Gulshan Yadav, MD**  
Consultant Pathologist