

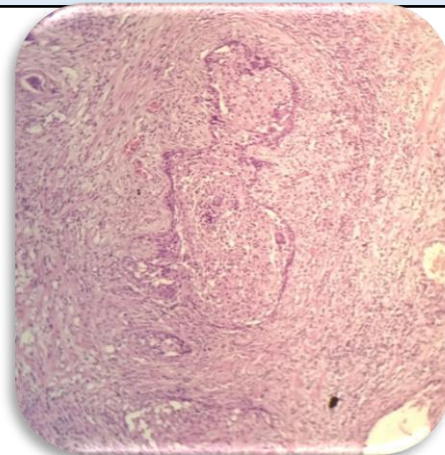
Patient Name	Mr. MAKHAN LAL-21544	Client Name	Pushpanjali Hospital	Specimen Received	17/12/2018
Age/Sex	65 Years/Male		(Rewari))	Specimen Type	Tissue
Patient ID	011812170219	Client Code	MolQ1789CM	Collection Date	17/12/2018
Specimen ID	MOLQ/B-1419/18	Ref. Doctor	DR.KAMAL	Report Date	20/12/2018

SURGICAL PATHOLOGY REPORT

TURP Chips

DIAGNOSIS

BENIGN PROSTATIC HYPERPLASIA WITH PROSTATITIS



SPECIMEN
TURP Chips

GROSS

Received multiple greyish white tissue piece 4x5 cm in aggregate.

Microscopy

1. Section examined shows bilayered prostatic glands with columnar lining epithelium and with small round to oval nucleus surrounded by large number of fibrocollagenous tissue and mononuclear inflammatory cell.

Note : All biopsy specimen will be stored for 15 (fifteen)days, block and slides for 5(five) years only from the time of receipt at the laboratory. No request ,for any of the above ,will be entertained after the due date.

Reference

- i) Rosai and Ackerman's Surgical Pathology.
- ii) Modern Surgical Pathology.

Gulshan Yadav, MD
Consultant Pathologist