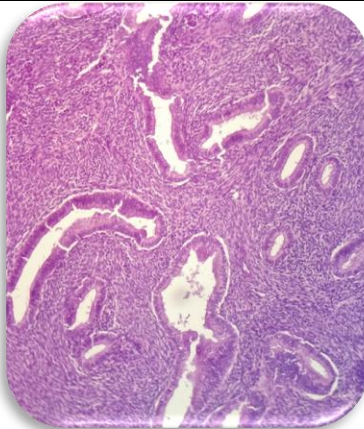


<b>Patient Name</b>	Mrs. SAROJ DEVI	<b>Client Name</b>	Pushpanjali Hospital (Rewari)	<b>Specimen Received</b>	15/12/2018
<b>Age/Sex</b>	49/F	<b>Client Code</b>	MolQ1789CM	<b>Specimen Type</b>	Tissue
<b>Patient ID</b>	011812150241	<b>Ref. Doctor</b>	DR KIRAN	<b>Collection Date</b>	15/12/2018
<b>Specimen ID</b>	MOLQ/B-1411/18			<b>Report Date</b>	19/12/2018

## SURGICAL PATHOLOGY REPORT

### ENDOMETRIUM

#### SIMPLE HYPERPLASIA WITHOUT ATYPIA



#### SPECIMEN

Endometrium

#### GROSS

Received multiple greyish white tissue piece.

#### Microscopy

1. Section examined shows small and dilated endometrial glands having round to oval nucleus. Stroma shows mononuclear inflammatory cells.
2. No malignant and no granuloma seen.

**Note :** All biopsy specimen will be stored for 15 (fifteen) days, block and slides for 5 (five) years only from the time of receipt at the laboratory. No request for any of the above, will be entertained after the due date.

#### Reference

- i) Rosai and Ackerman's Surgical Pathology.
- ii) Modern Surgical Pathology.

**Gulshan Yadav, MD**  
Consultant Pathologist