

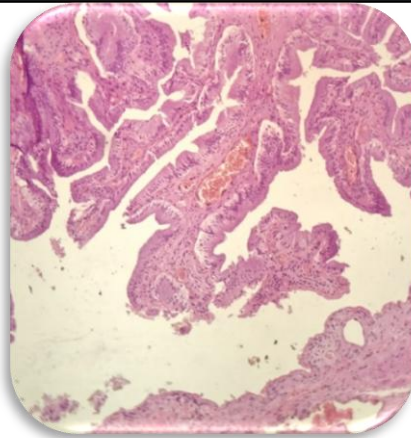
<b>Patient Name</b>	<b>Mr. PRAVEEN CHOUKAR</b>	<b>Client Name</b>	Pushpanjali Hospital	<b>Specimen Received</b>	14/12/2018
<b>Age/Sex</b>	30/M		(Rewari)	<b>Specimen Type</b>	Tissue
<b>Patient ID</b>	011812140191	<b>Client Code</b>	MolQ1789CM	<b>Collection Date</b>	14/12/2018
<b>Specimen ID</b>	MOLQ/B-1396-18	<b>Ref. Doctor</b>	DR.KULDEEP	<b>Report Date</b>	18/12/2018

## SURGICAL PATHOLOGY REPORT

### Pilonidal sinus

#### DIAGNOSIS

### NON-SPECIFIC INFLAMMATION



#### SPECIMEN

Pilonidal sinus

#### GROSSING

Received 7x4 cm tissue with sinus tract.

#### Microscopy

- Section examined shows squamous lining epithelial with fibro collagenous tissue, blood vessels, hair follicle, mature adipose cells, inflammatory cells and mild hyperkeratosis.

**Note :** All biopsy specimen will be stored for 15 (fifteen) days, block and slides for 5 (five) years only from the time of receipt at the laboratory. No request for any of the above will be entertained after the due date.

#### Reference

- Rosai and Ackerman's Surgical Pathology.
- Modern Surgical Pathology
- Shafers, 7<sup>th</sup> Edition

**Gulshan Yadav, MD**  
Consultant Pathologist